

Comparison of anterior segment changes, before and after laser peripheral iridectomy (PI) by using anterior segment optical coherence tomography (AS OCT) in eyes suspected of narrow anterior chamber angles

J. M. W. Wajirani¹, U. A. K. Thennekumbura¹, D. H. H. Wariyapola²

The Journal of the College of Ophthalmologists of Sri Lanka 2015; 21: 12-15

Abstract

Objectives:

- 1) To compare pre and post conventional Laser PI, angle and anterior chamber dimensions in eyes with angle closure suspects by using anterior segment OCT (visante).
- 2) To identify types of angle closure suspects such as plateau iris.

Methodology: A prospective observational study in 40 eyes of 20 patients recruited from the Eye Clinic at SJGH from January 2014 to July 2014. AS OCT images of temporal and nasal angles and anterior chamber taken in each eye before and after PI. Main outcome measures were, temporal and nasal trabeculo-iris angles (TIA), central anterior chamber depth (ACD). Comparison made between pre and post AS dimension data.

Results: 58 eyes of 29 subjects were analysed. Pre and post Laser PI anterior chamber data were compared. There were significant increase in TIA and ACD following PI.

Conclusion: In eyes suspected of having angle closure, Laser PI resulted in significant angle widening and anterior chamber deepening based on AS OCT imaging.

Introduction

Angle-closure glaucoma (ACG) affects an estimated 16 million people worldwide. The global presence of ACG is approximately one-third that of open-angle glaucoma. The number of people blind due to ACG (3.9 million) is nearly equal to that blinded by OAG.

The anterior segment optical coherence tomography (AS OCT) provides an objective method to assess the anterior segment of the eye.

This technology allows both qualitative and quantitative analyses of the angle.

Anterior segment OCT uses the principle of low-coherence interferometry. It produces high-resolution, cross sectional images of the anterior segment of the eye. The wave length is 1310 nm.

Objectives

- 1) To compare pre and post conventional Laser PI, angle and anterior chamber dimensions in eyes with angle closure suspects by using anterior segment OCT (visante).
- 2) To identify types of angle closure suspects such as plateau iris.

Methodology

It is a prospective observational study. 58 eyes of 29 patients who are suspects of having narrow anterior chamber angles attended the Eye Clinic SJGH from December 2013 to July 2014 were included to the study. Gonioscopy performed in order to define the narrow angles. AS OCT imaging was performed by single examiner, tomographical cross sections of the anterior chamber in horizontal meridian were taken. The line joining the scleral spurs of temporal and nasal angles was used as a fixed reference to obtain the measurements.

Measurements taken

- 1) Central anterior chamber depth (cACD).
- 2) Angle opening distance 500mic (AOD 500) of temporal and nasal angles were measured.
- 3) Iris and angle morphology were observed qualitatively.

Routine YAG Laser PI were performed at 10 to 11 o'clock position of right eyes and 2 o'clock position in the left eyes of patients with narrow angles (based on slit lamp and gonioscopic confirmation).

¹Senior Registrar in Ophthalmology, ²Consultant Ophthalmologist, Sri Jayewardenepura General Hospital, Sri Lanka.

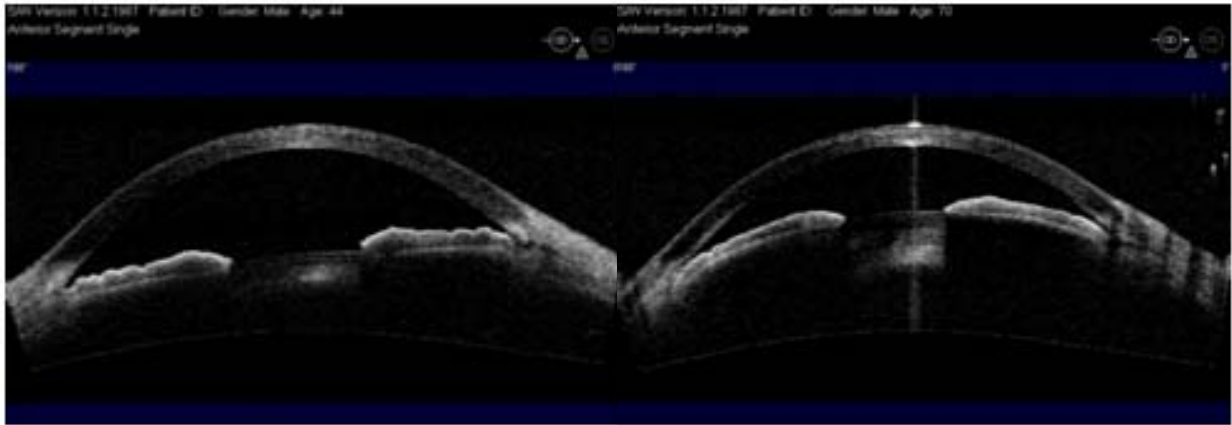
Post PI, AS OCT performed in all eyes at least after two weeks and above mentioned measurements were repeated by the same examiner using anterior segment OCT.

Eyes with peripheral anterior synchia, pigments, pseudoexfoliation and neovascularization in the anterior chamber angle were excluded.

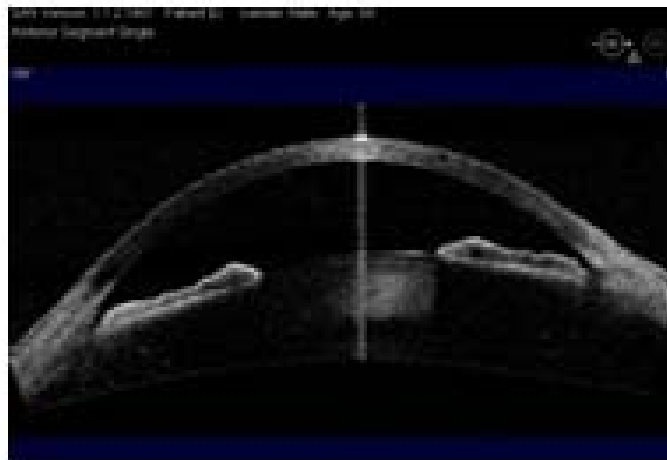
Eyes with significant cataract were excluded.

Results

There were ten male and 18 females included in the study. Age distribution of patients were between 35yrs to 80yrs. By using anterior segment OCT photographs, 20 patients with plateau iris configuration identified and 13 patients with pure narrow angles identified, while 25 patients identified as having mixed features of both narrow angles and plateau isis configuration.



Narrow angle AS OCT image



Mixed group AS OCT image

Results

Pleateau iris group

Mean pre PI, central anterior chamber depth was 2.46 mm while post PI central anterior chamber depth was 2.56 mm. There was a statistically significant increase in central anterior chamber depth after PI. Mean pre PI angle opening distance at 500mic in nasal angle was 0.18mic while post PI nasal angle opening distance at 500mic was 0.28mic. There was no statistically significant increase in nasal angle opening distance at 500mic after PI. Mean pre PI angle opening distance at 500mic in temporal angle was 0.31mic while post PI nasal angle opening distance at 500mic was 0.77mic. There was no statistically significant increase in temporal angle opening distance at 500mic after PI.

Mean value	Pre op	Post op	Significance
cACD (mm)	2.46 ± 0.22	2.56 ± 0.21	P<0.01
AOD nasal (µm)	0.18 ± 0.01	0.28 ± 0.02	P>0.05
AOD temporal	0.31 ± 0.03	0.77 ± 0.04	P>0.05

Narrow angle group

Mean pre PI central anterior chamber depth was 1.90mm while post PI central anterior chamber depth was 1.99mm. There was a statistically significant increase in central anterior chamber depth after PI. Mean pre PI angle opening distance at 500mic in nasal angle was 0.16mic while post PI nasal angle opening distance at 500mic was 0.20mic. There was no statistically significant increase in nasal angle opening distance at 500mic after PI. Mean pre PI angle opening distance at 500mic in temporal angle was 0.11mic while post PI nasal angle opening distance at 500mic was 0.18mic. There was statistically significant increase in temporal angle opening distance at 500mic after PI.

Mean value	Pre op	Post op	Significance
cACD (mm)	1.90 ± 0.02	1.99 ± 0.12	P<0.05
Nasal AOD 500(µm)	0.16 ± 0.12	0.20 ± 0.02	P>0.05
Temporal AOD 500	0.11 ± 0.02	0.18 ± 0.03	P<0.05

Mixed group

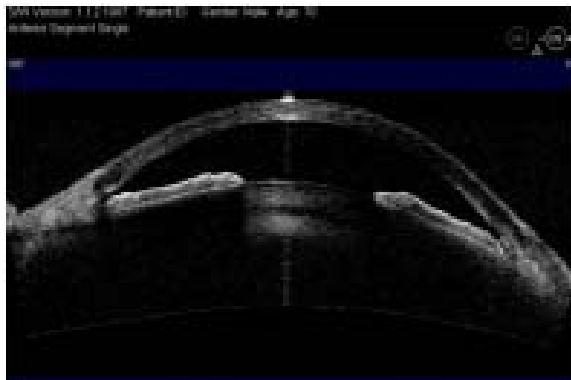Mean pre PI central anterior chamber depth was 2.24mm while post PI central anterior chamber depth was 2.31mm. There was a statistically significant increase in central anterior chamber depth after PI. Mean pre PI angle opening distance at 500mic in nasal angle was 0.19mic while post PI nasal angle opening distance at 500mic was 0.29mic. There was no statistically significant increase in nasal angle opening distance at 500mic after PI. Mean pre PI angle opening distance at 500mic in temporal angle was 0.18mic while post PI nasal angle opening distance at 500mic was 0.27mic. There was statistically significant increase in temporal angle opening distance at 500mic after PI.

Mean value	Pre op	Post op	Significance
cACD (mm)	2.24 ± 0.22	2.31 ± 0.23	P<0.05
Nasal AOD 500(μm)	0.19 ± 0.01	0.29 ± 0.06	P>0.05
Temporal AOD 500	0.18 ± 0.01	0.27 ± 0.12	P<0.01

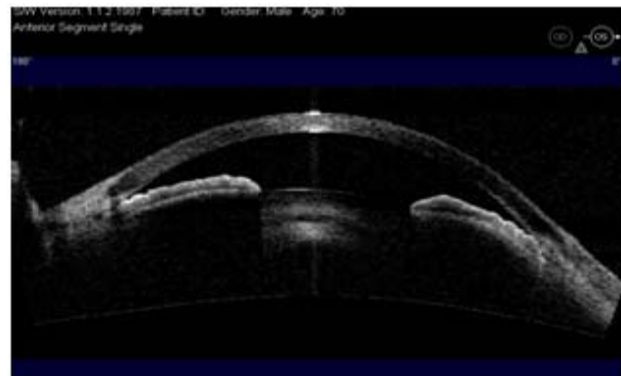
Discussion

Based on AS OCT findings all eyes with narrow angles showed significant increase in central anterior chamber depth measurements after Laser PI compared to pre PI measurements. Eyes with plateau iris configuration did not show statistically significant increase in nasal and temporal AOD 500mic after PI. Both the narrow angle and mixed groups demonstrated significant increase in temporal AOD at 500mic after PI. while no significant increase in nasal AOD 500mic in both groups.

The iris changed from convexity to flattening in all eyes with pure narrow angles based on AS OCT imaging.



Pre PI narrow angle



Post PI narrow angle

Conclusion

In eyes suspected of having narrow angles, Laser PI resulted in significant angle widening and anterior chamber deepening based on AS OCT imaging.

AS OCT is an useful method in diagnosis and follow up of angle closure suspects.

References

- Lei LK, Wang N, Wang L, Wang B. Morphological changes of the anterior segment after laser iridectomy in primary angle closure. *Eye* 2009; **23**: 345-50.
- Li M, Liu X, Zhong YM, Zeng YF, Kong XY, Cao D, Guo XX. Comparison of anterior segment changes before and after laser peripheral iridectomy by anterior segment optical coherence tomography in eyes with primary acute angle closure glaucoma.